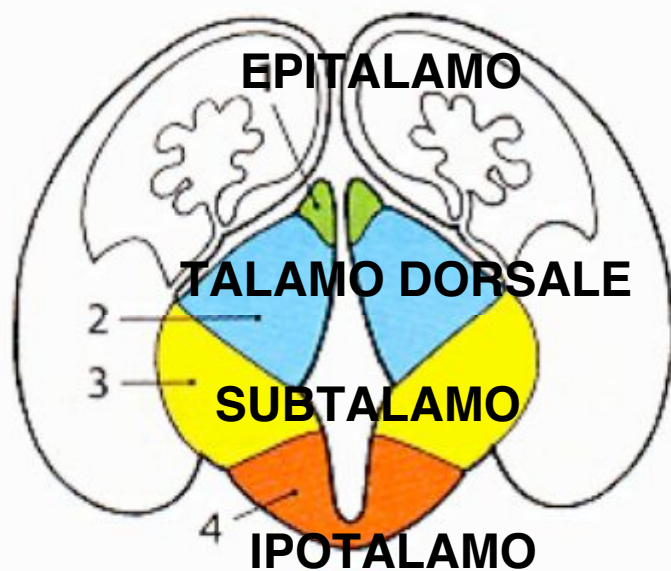


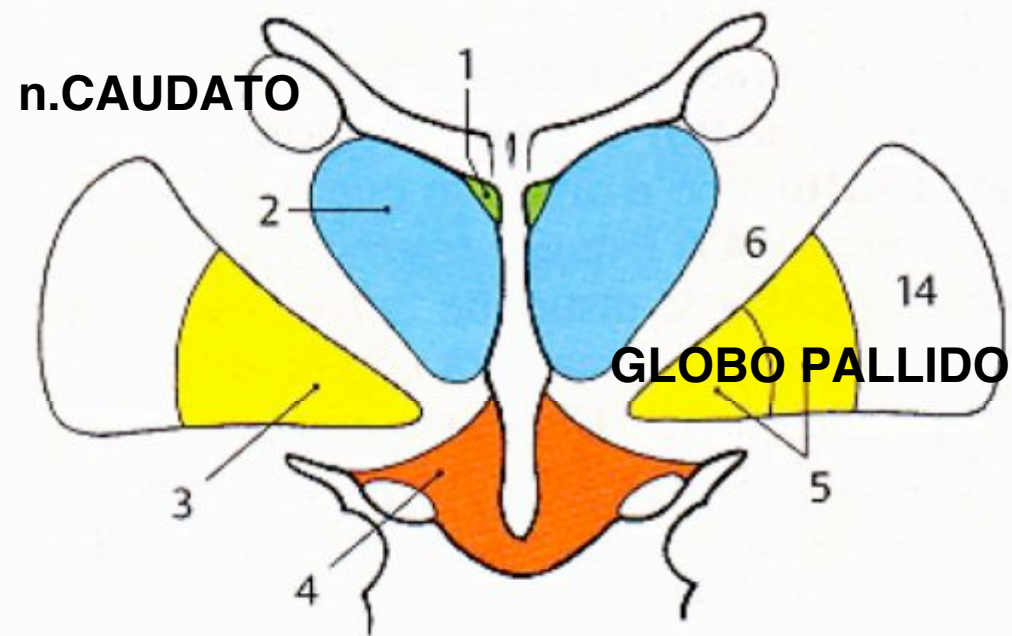
# DIENCEFALO

- Epitalamo
- Talamo
- Ipotalamo

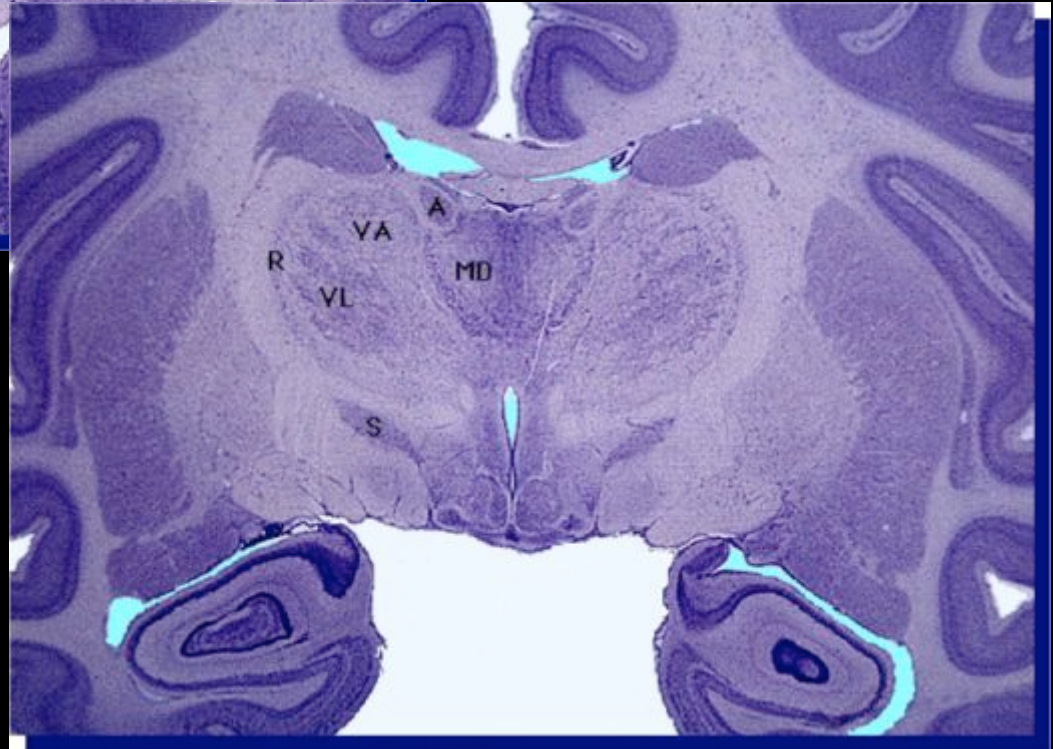
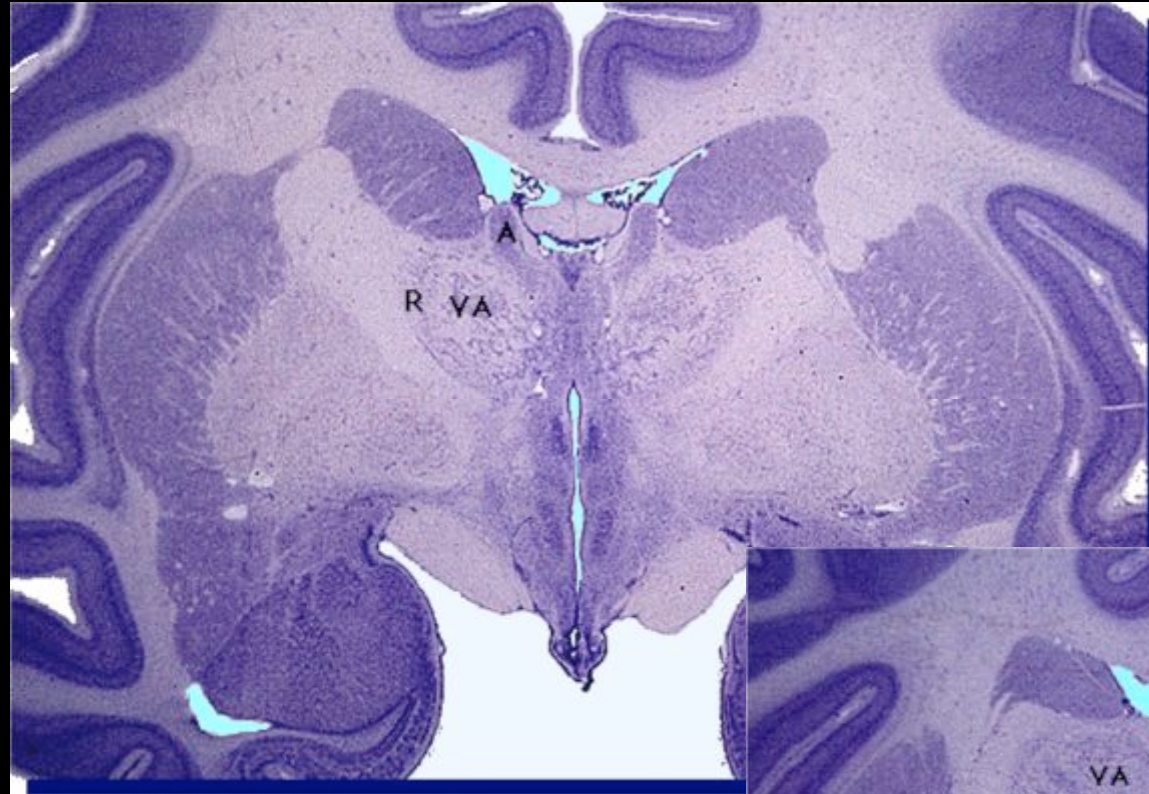
# Sviluppo del diencefalo



**B** Morfologia del diencefalo nell'embrione



**C** Morfologia del diencefalo nell'adulto

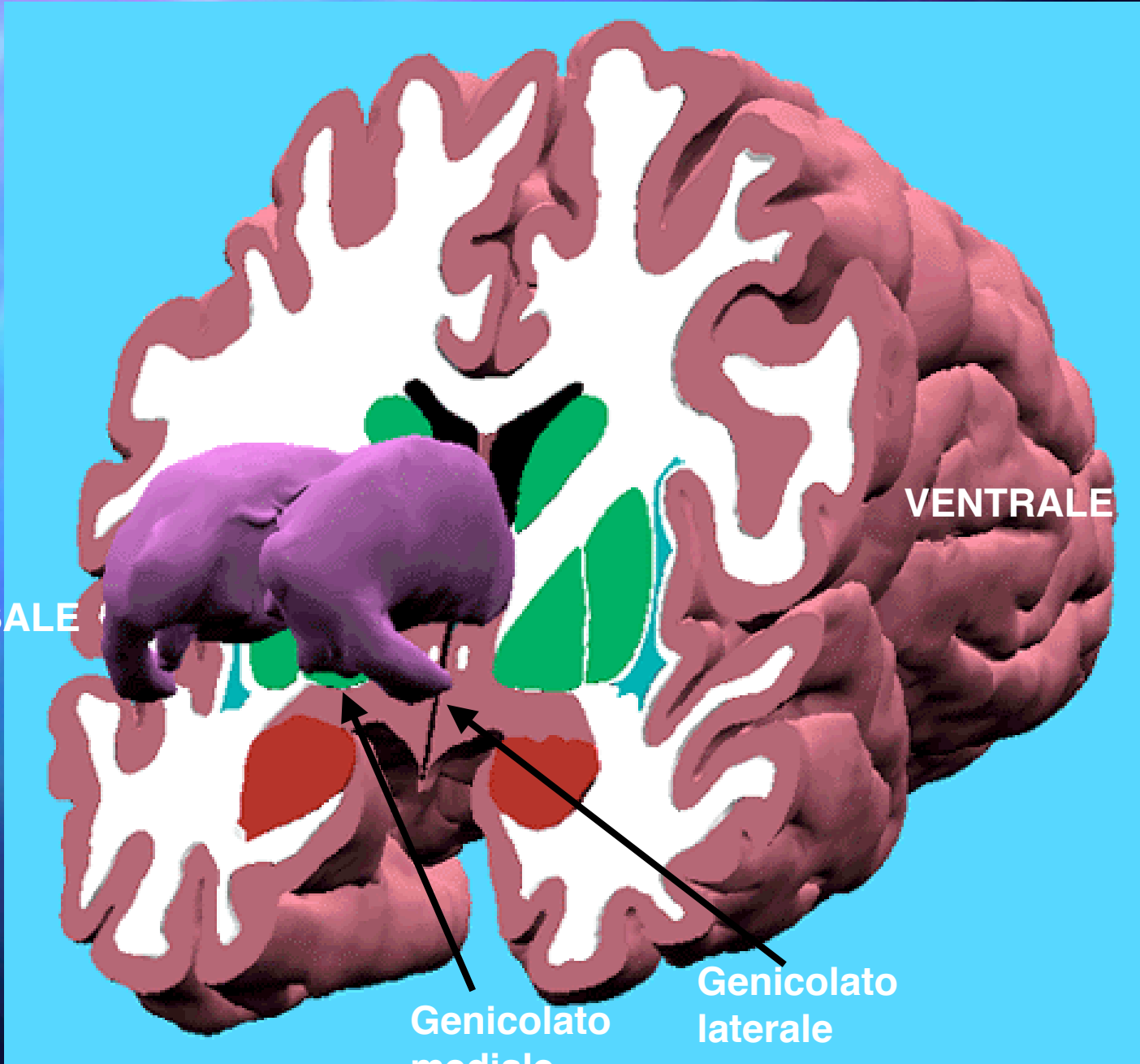


DORSALE

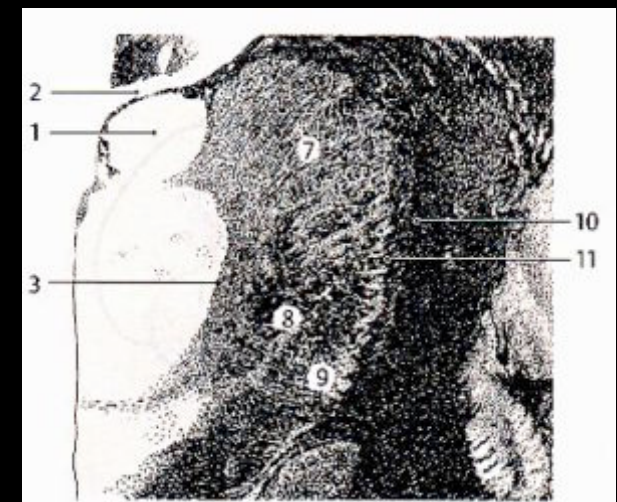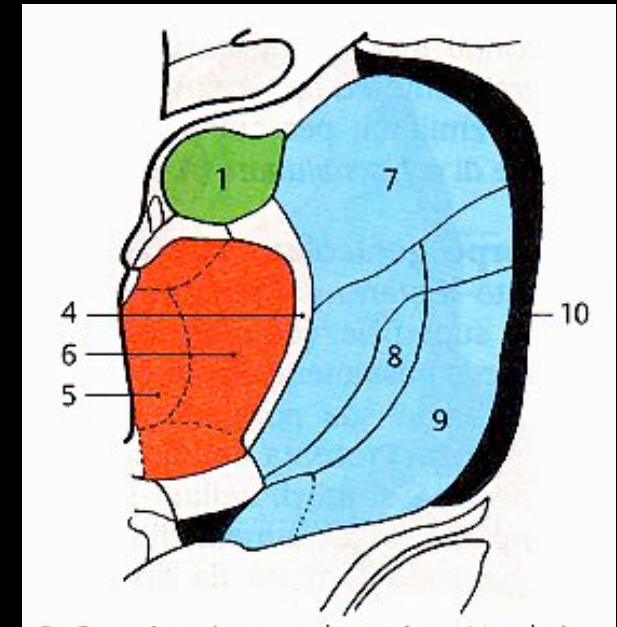
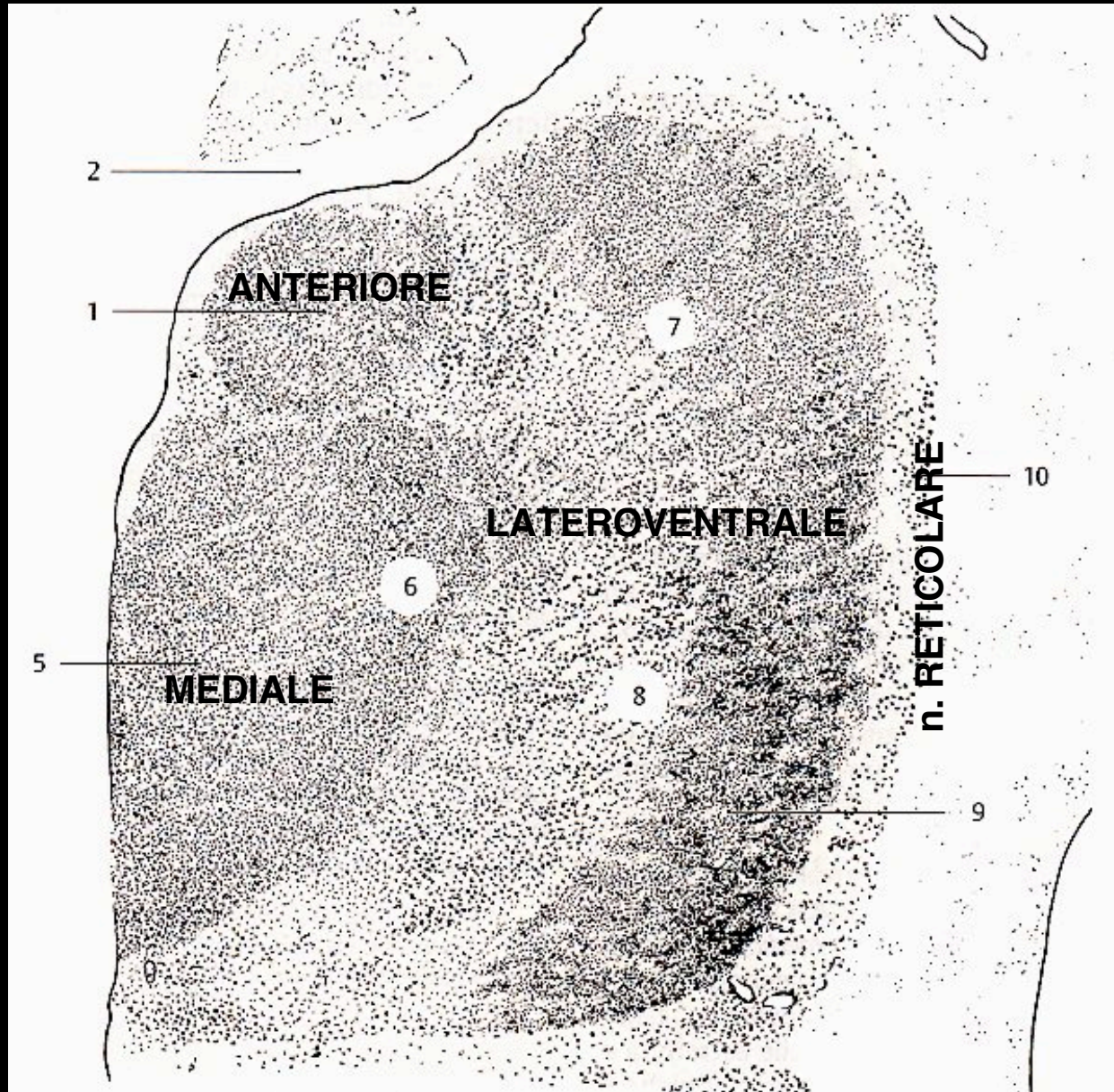
VENTRALE

Genicolato  
mediale

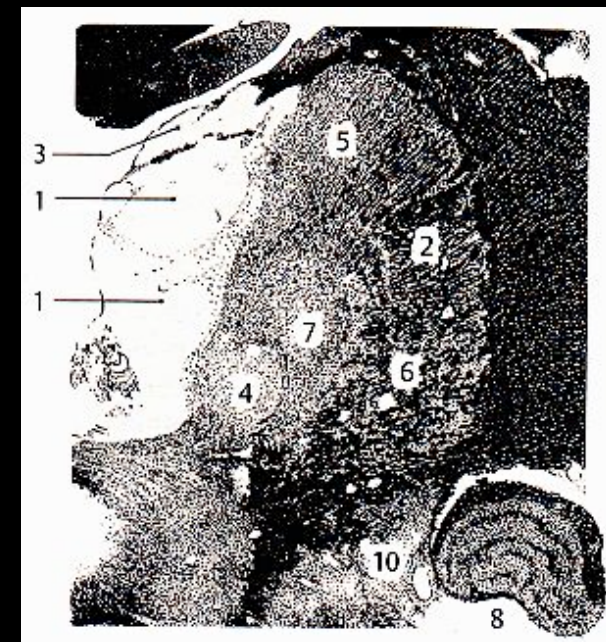
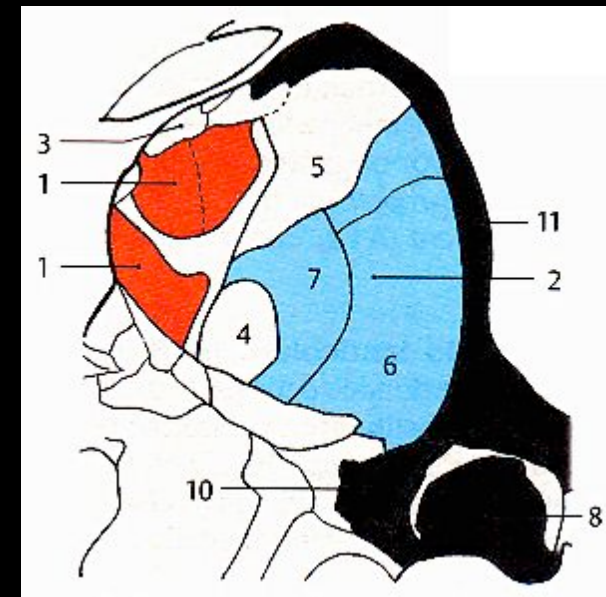
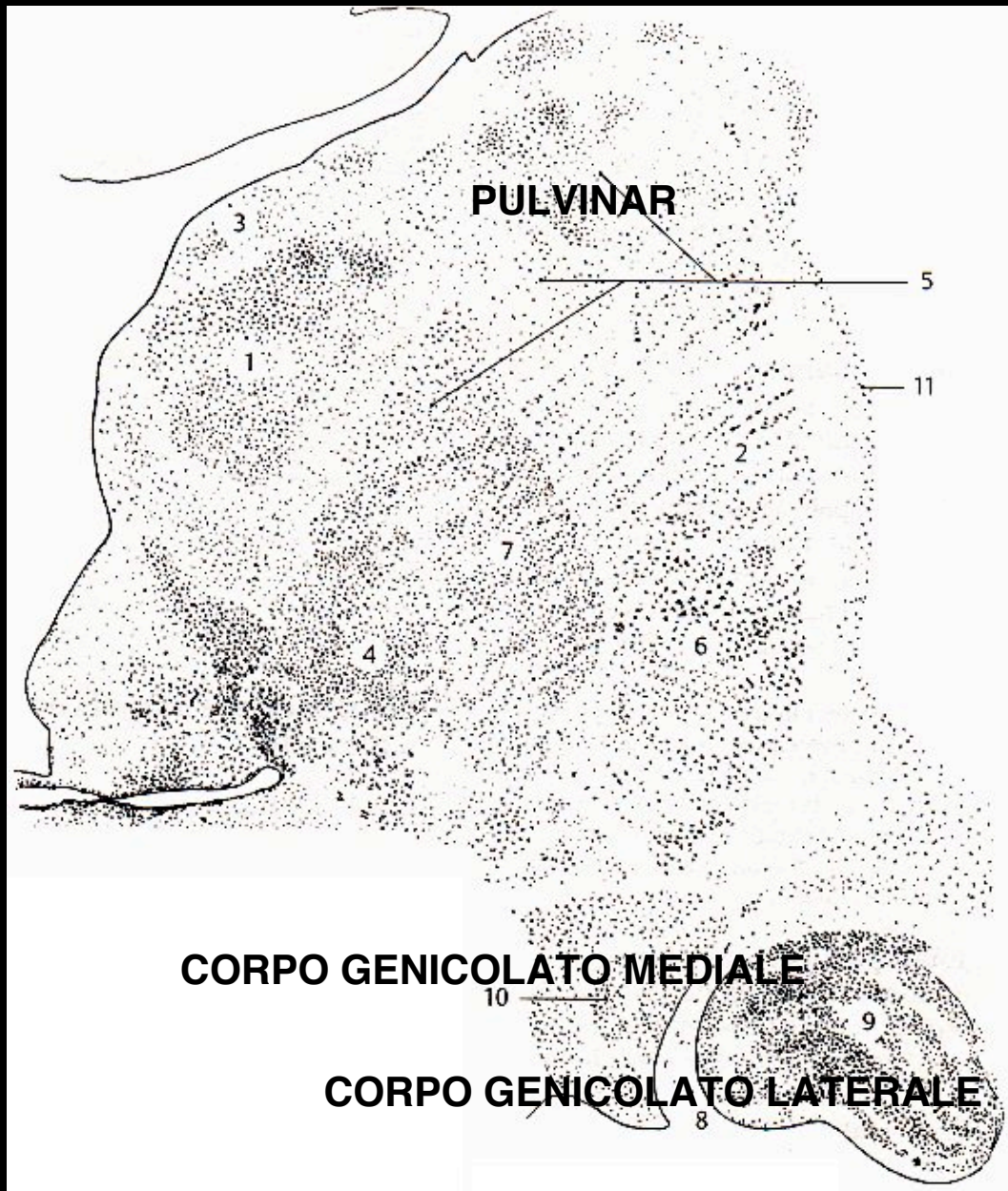
Genicolato  
laterale



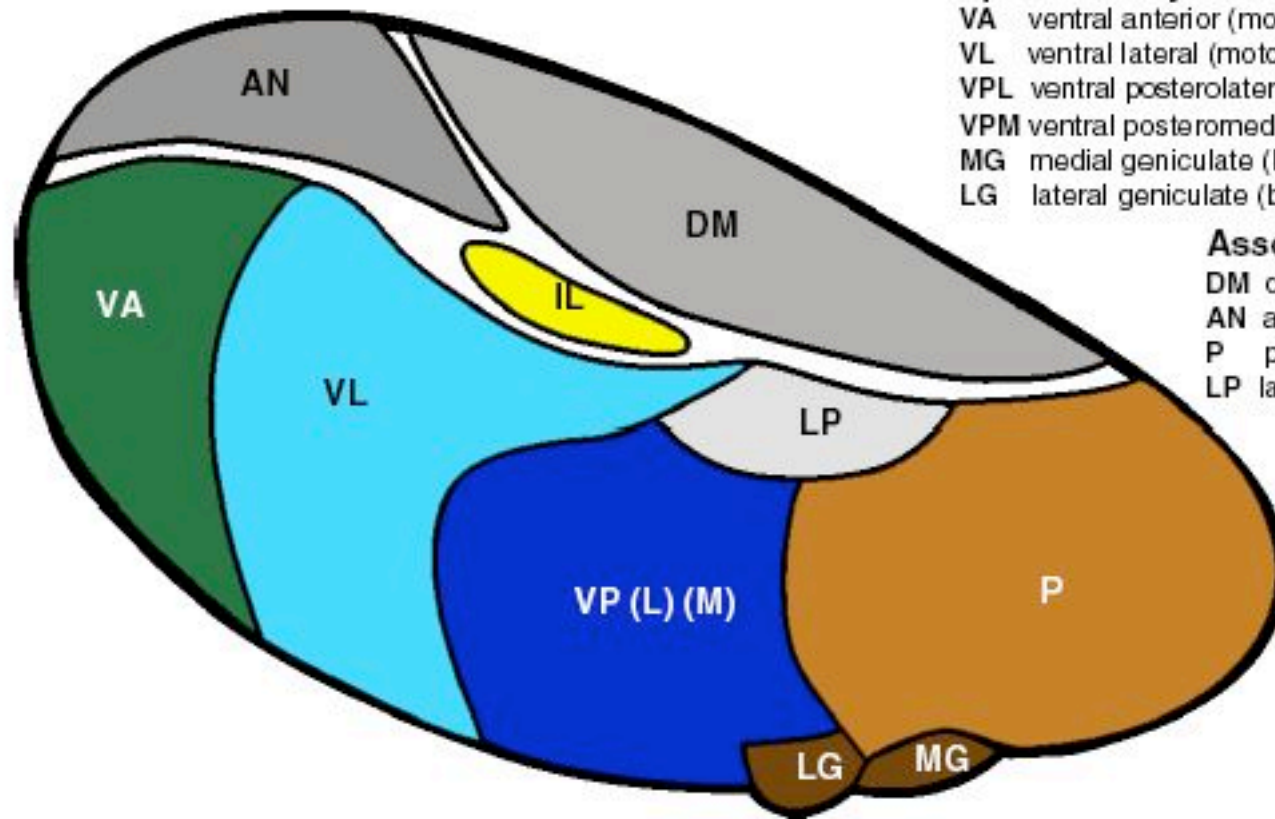
# Organizzazione del talamo



# Organizzazione del talamo



## THALAMUS - NUCLEI



### Specific relay nuclei

- VA ventral anterior (motor)
- VL ventral lateral (motor)
- VPL ventral posterolateral (somatosensory)
- VPM ventral posteromedial (trigeminal)
- MG medial geniculate (body) nucleus (auditory)
- LG lateral geniculate (body) nucleus (vision)

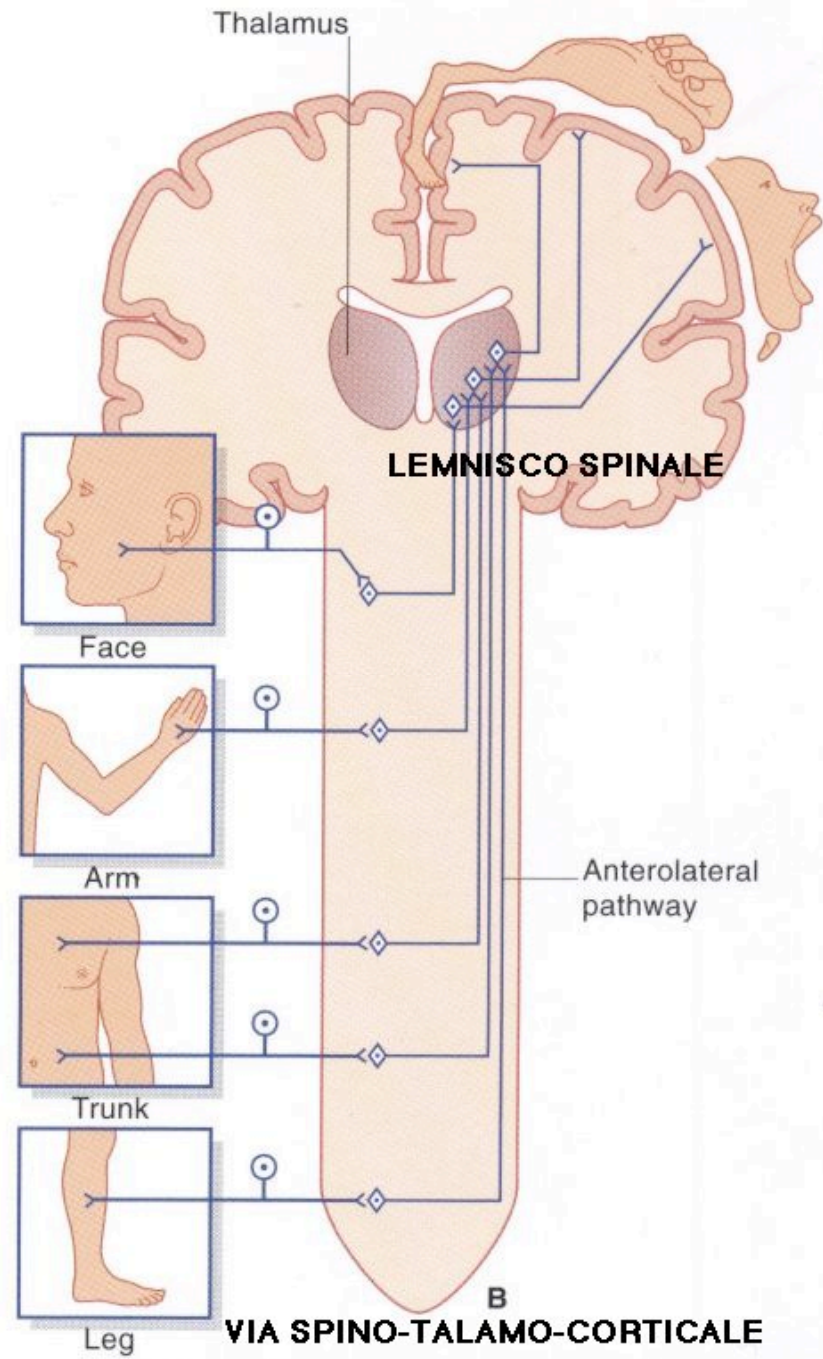
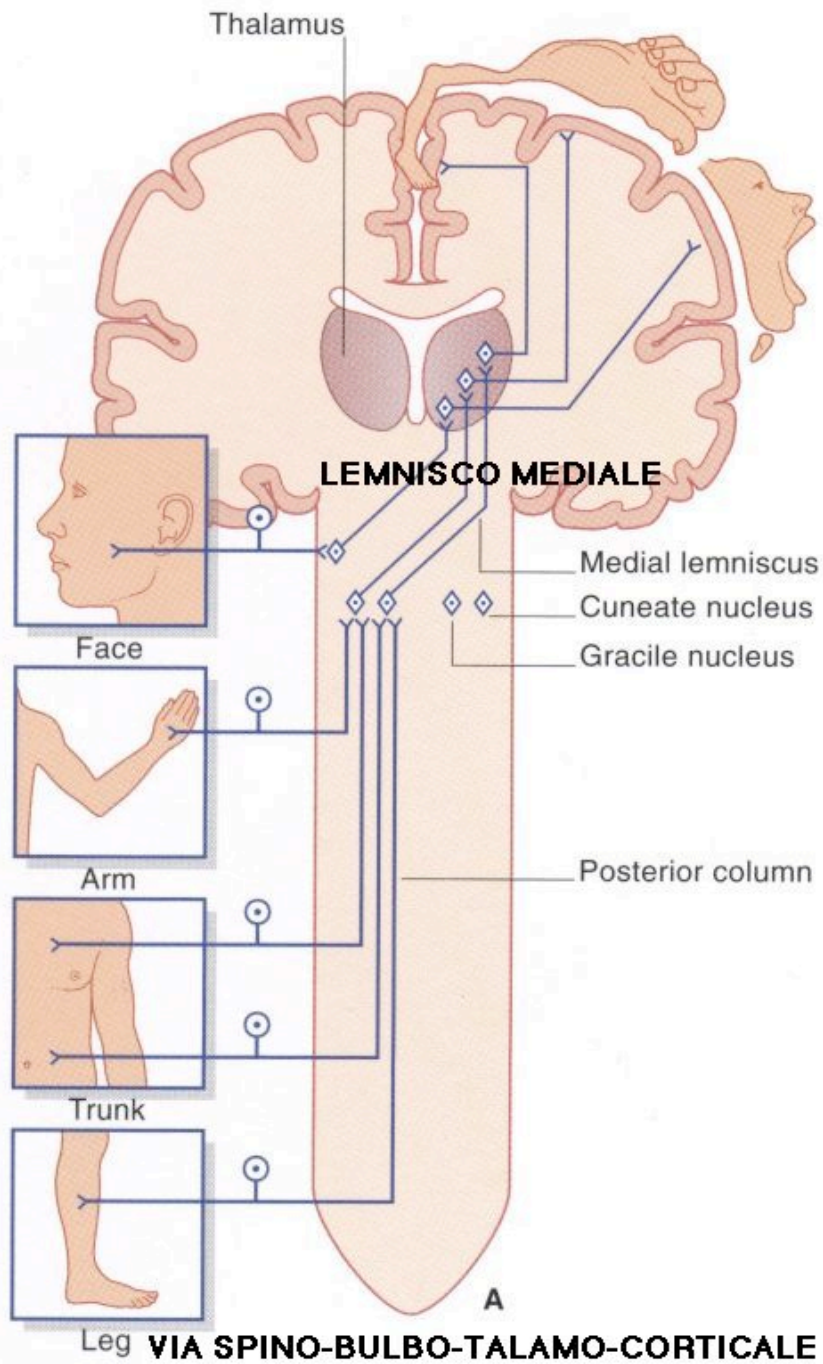
### Association nuclei

- DM dorsomedial nucleus (prefrontal cortex)
- AN anterior nucleus (limbic lobe)
- P pulvinar (visual cortex)
- LP lateral posterior (parietal lobe)

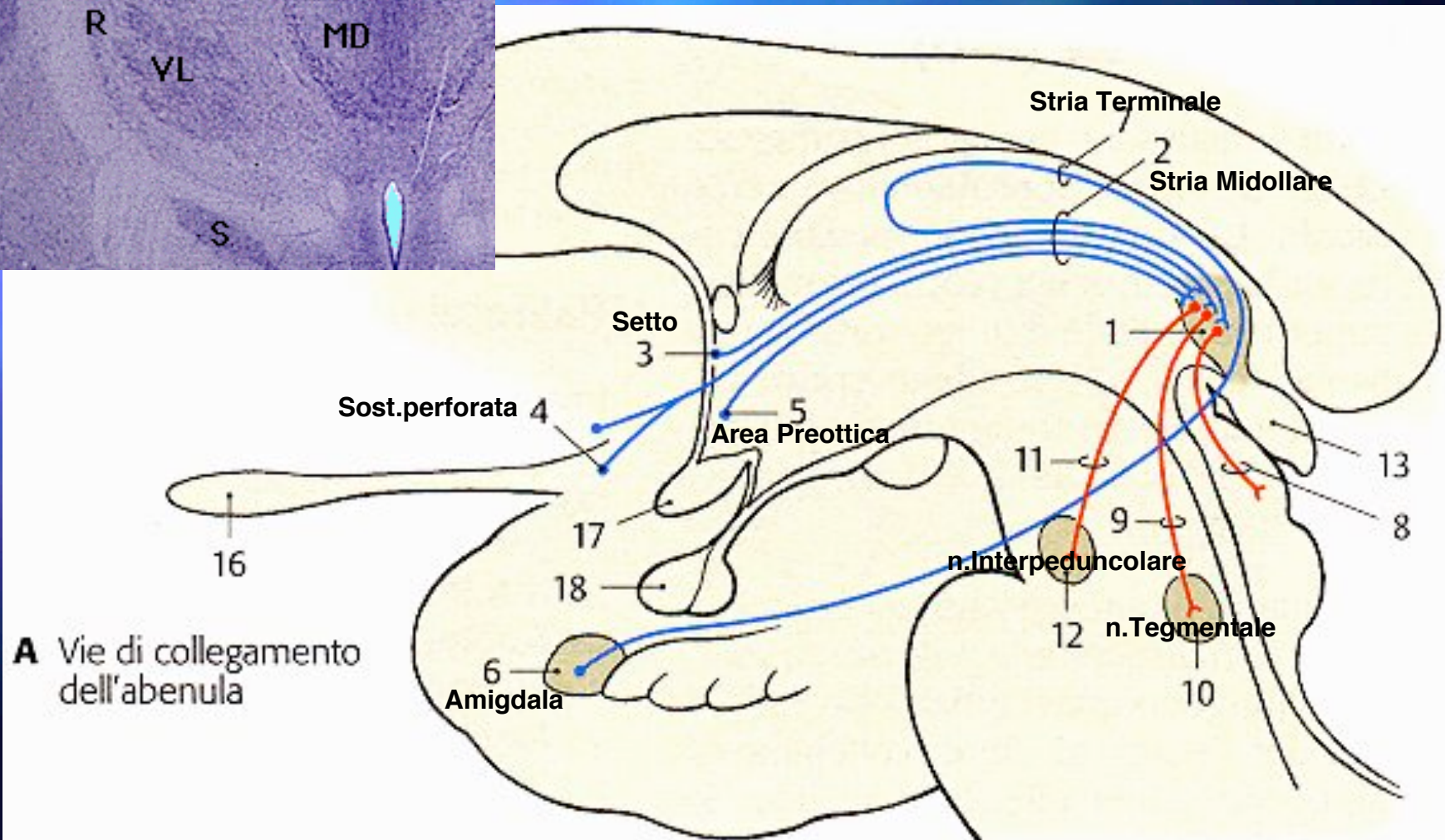
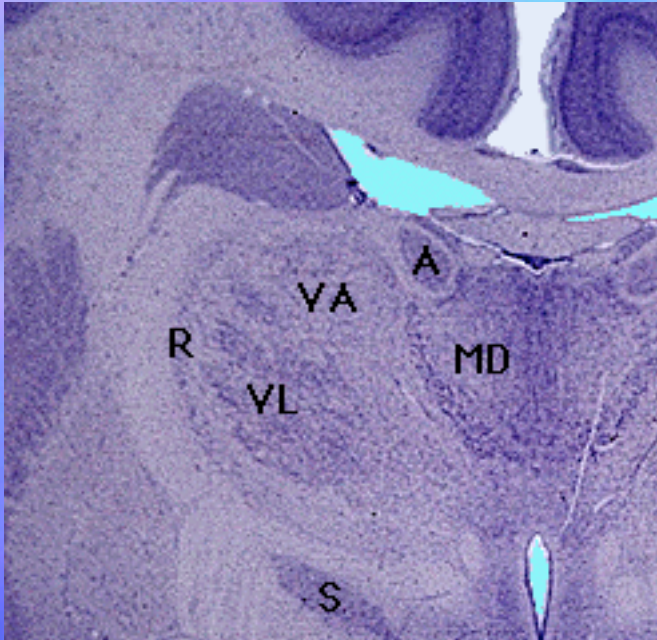
### Nonspecific nuclei

- IL intralaminar

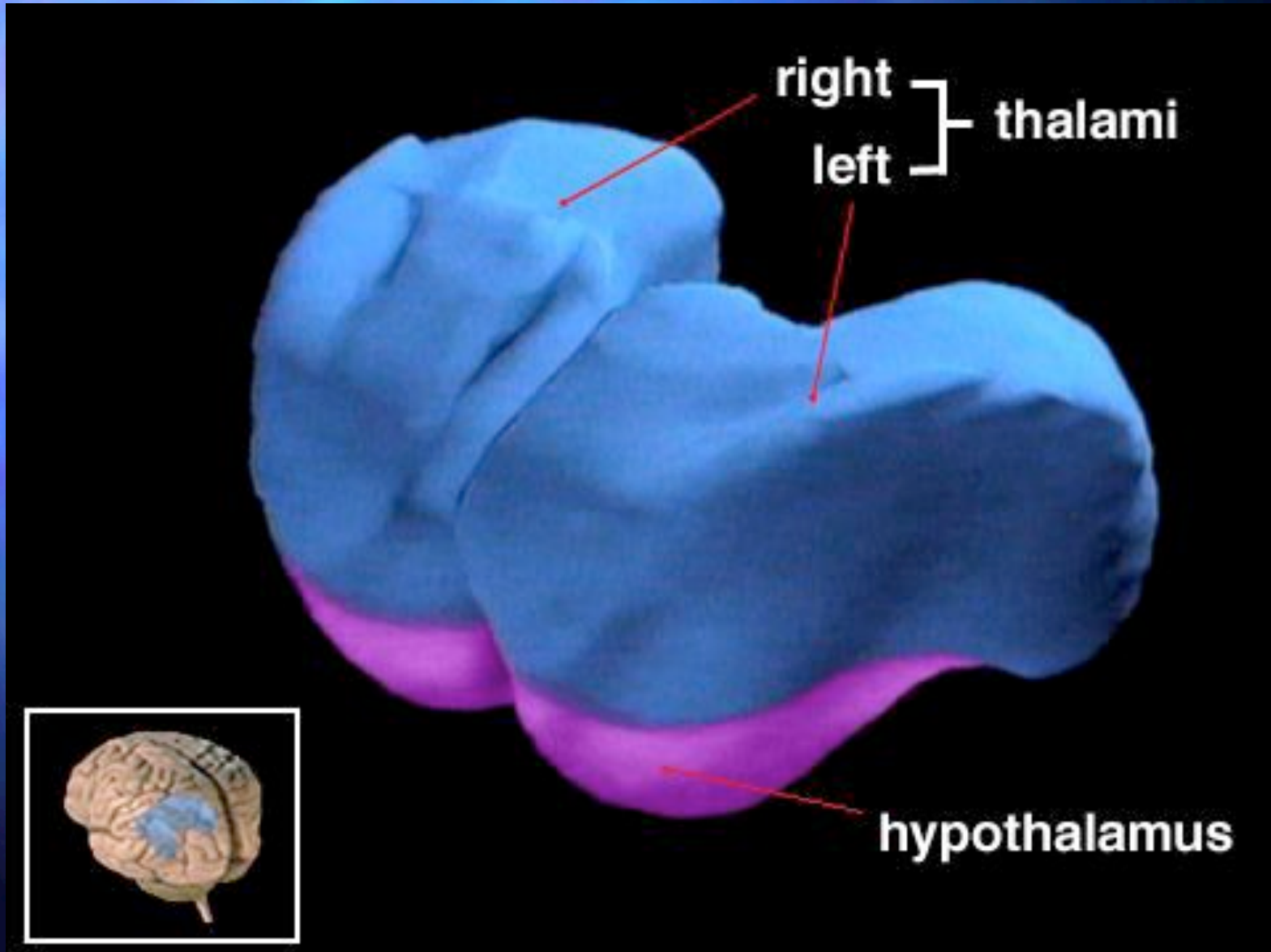
The thalamus and its various nuclei are shown diagrammatically. These nuclei are divided into three types, functionally - relay, association and nonspecific. The role of each should be reviewed as one studies the sensory and motor pathways, as well as the various parts of the cerebral cortex.

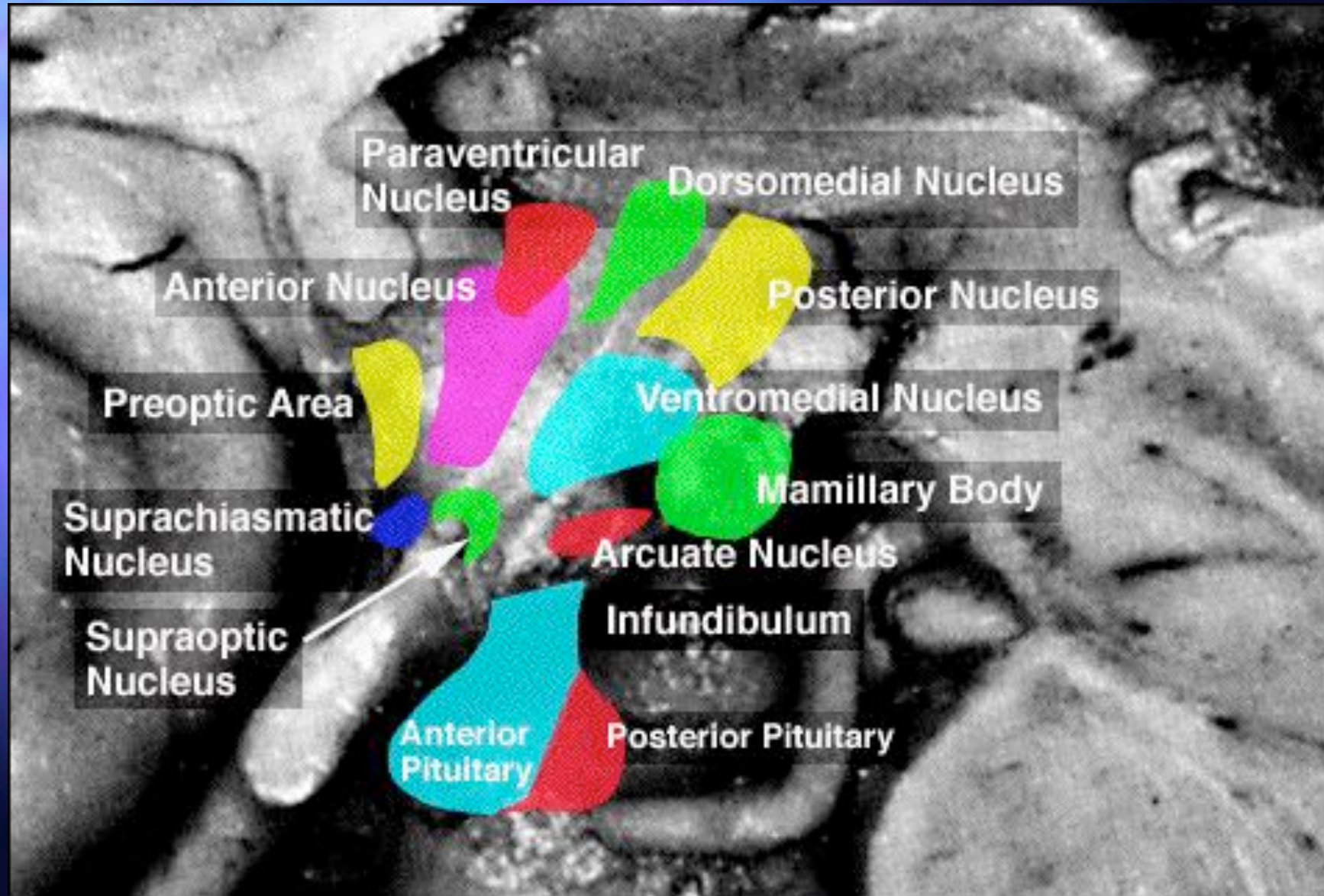


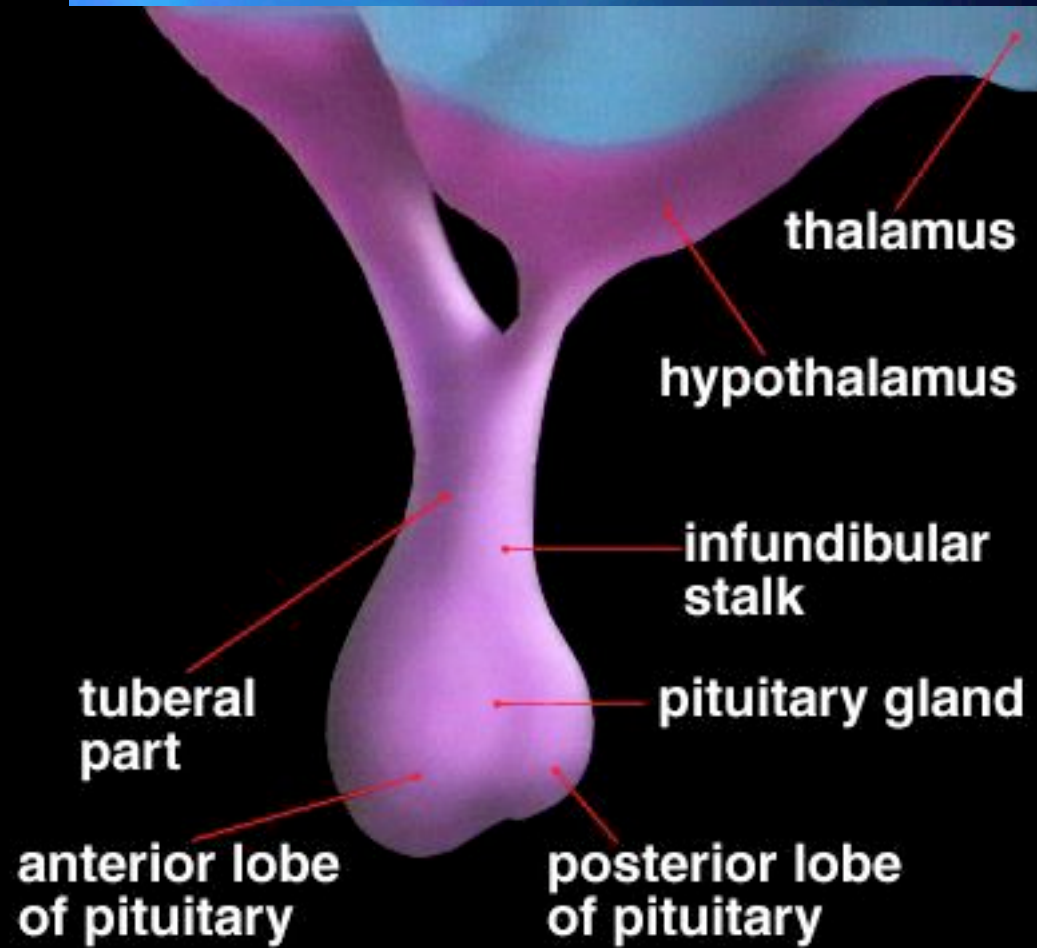

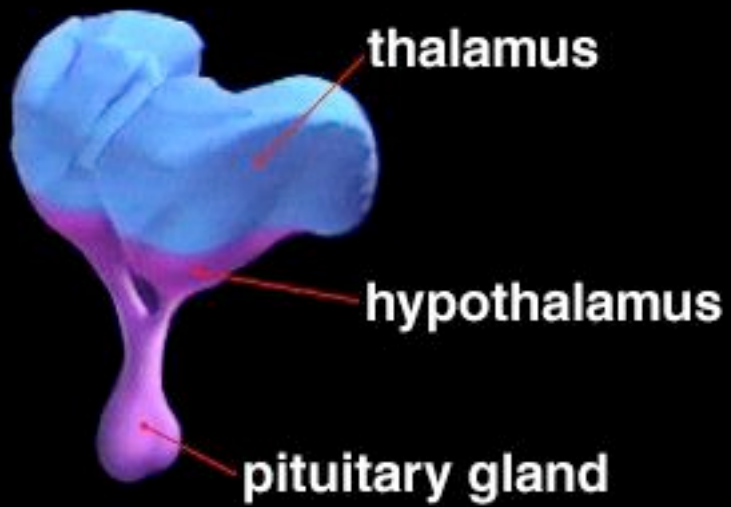
# Epitalamo

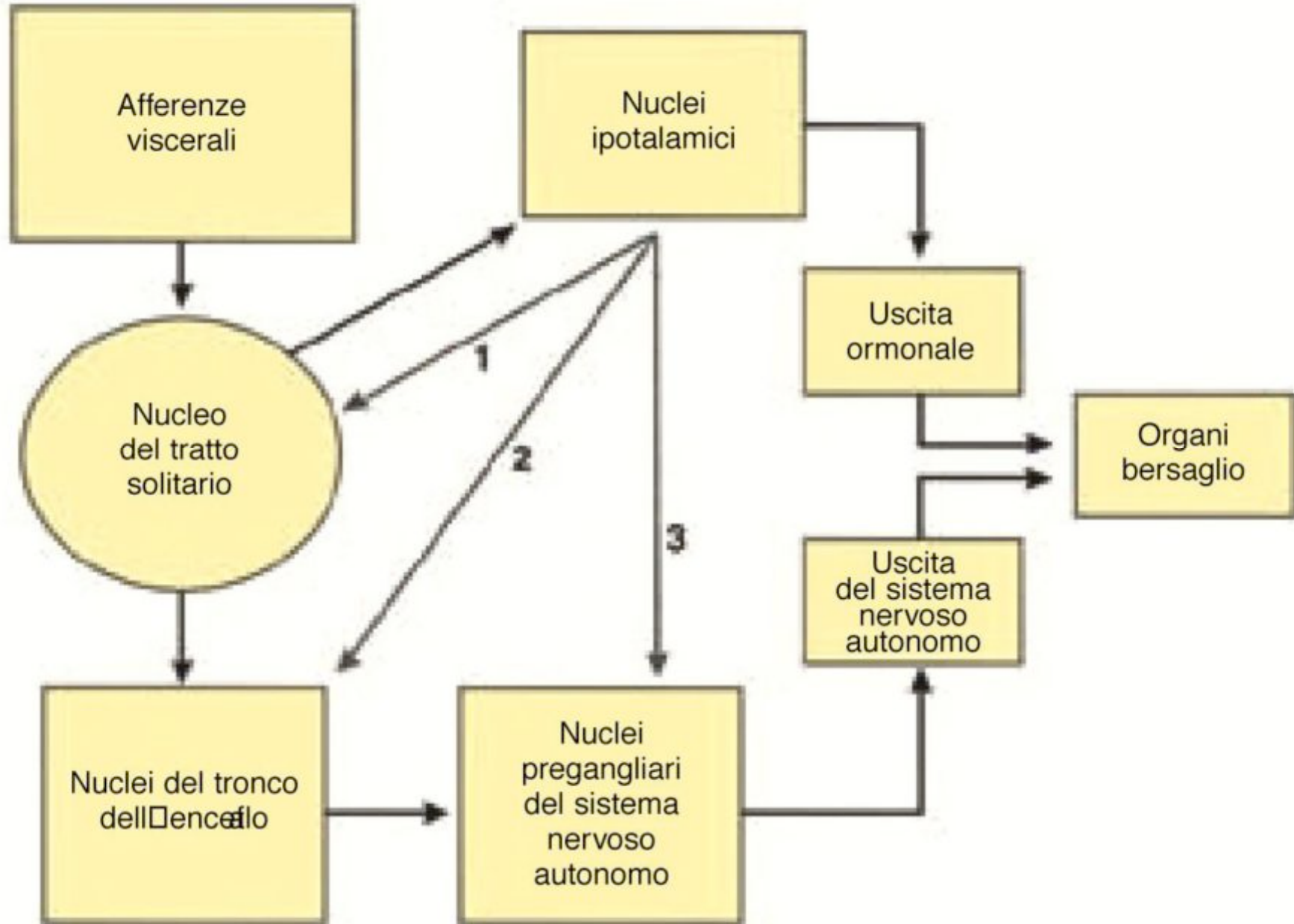


# IOTALAMO





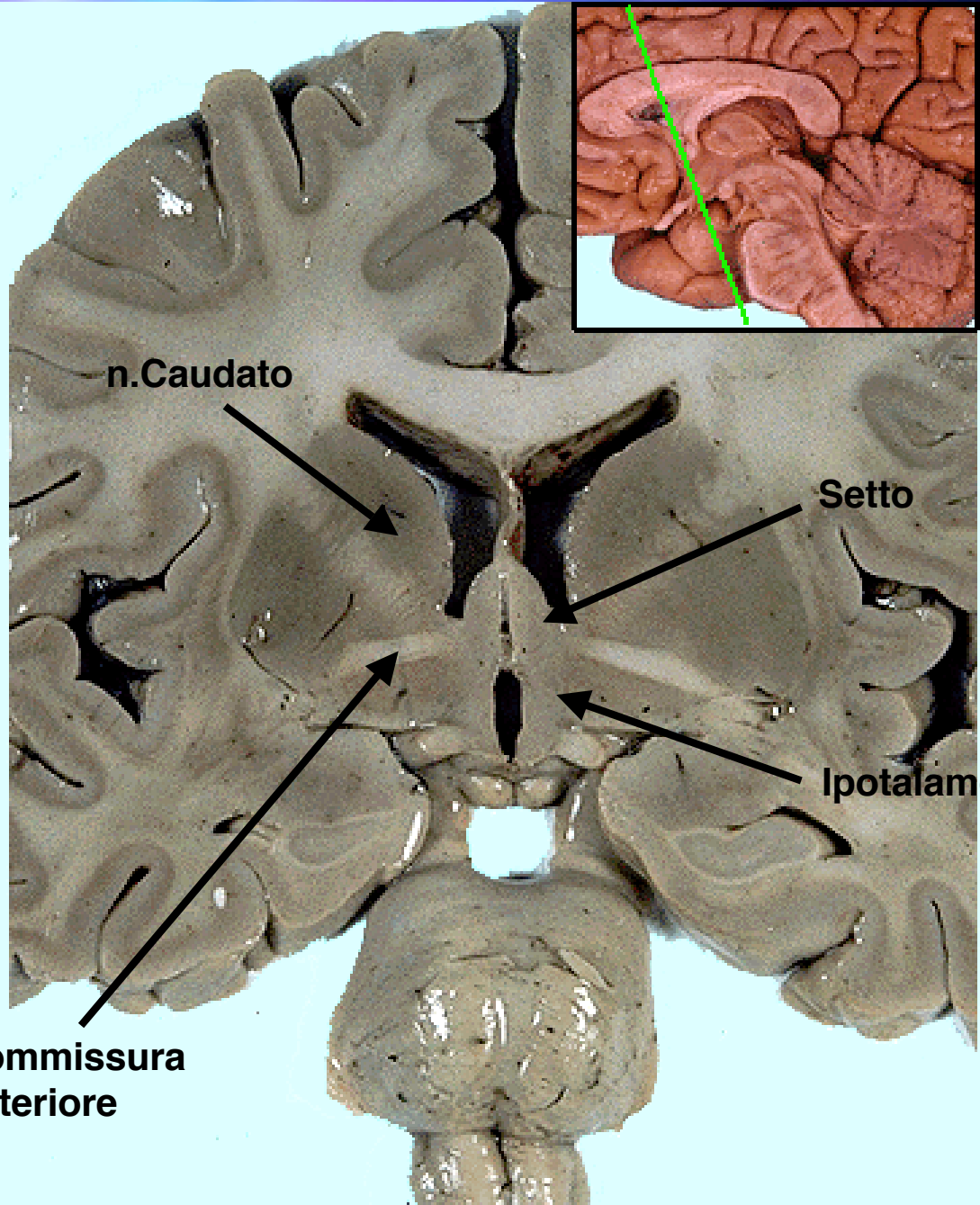




# IL SISTEMA NERVOSO CENTRALE COME ORGANO ENDOCRINO

- ✓ IPOTALAMO
- ✓ NEUROPEPTIDI
- ✓ NEUROSTEROIDI

# IPOOTALAMO



n.Caudato

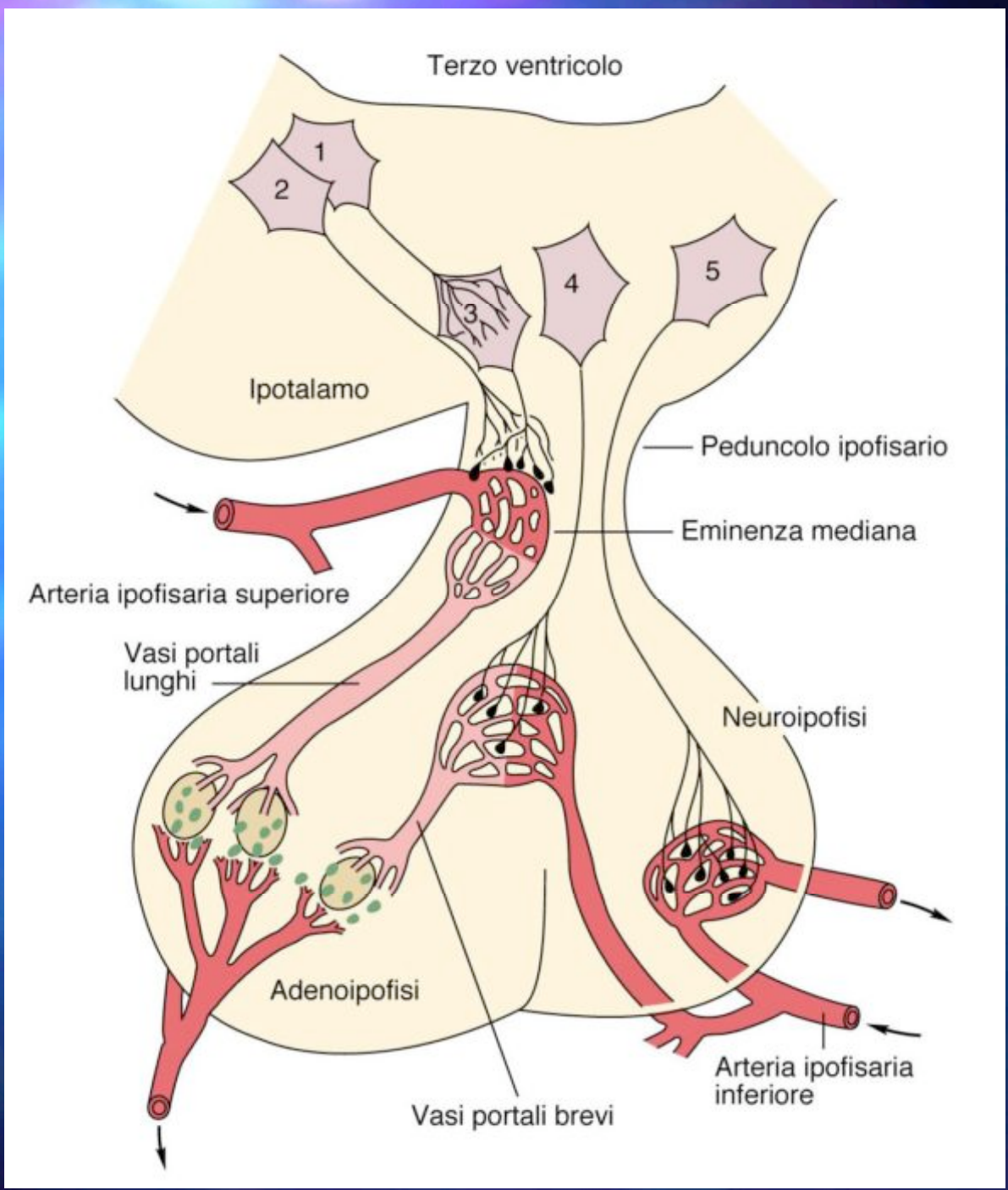
Setto

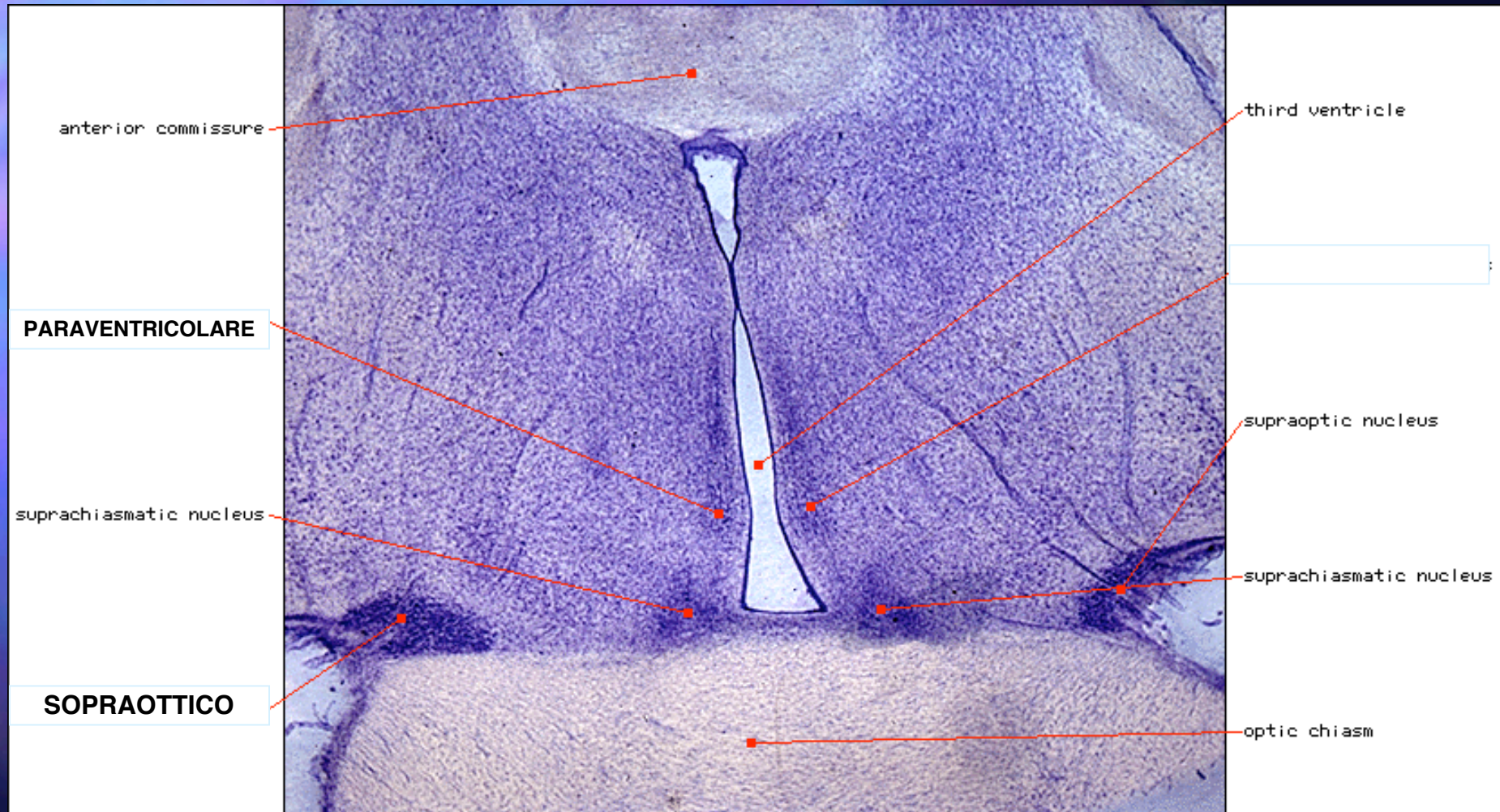
Ipotalamo

Commissura anteriore

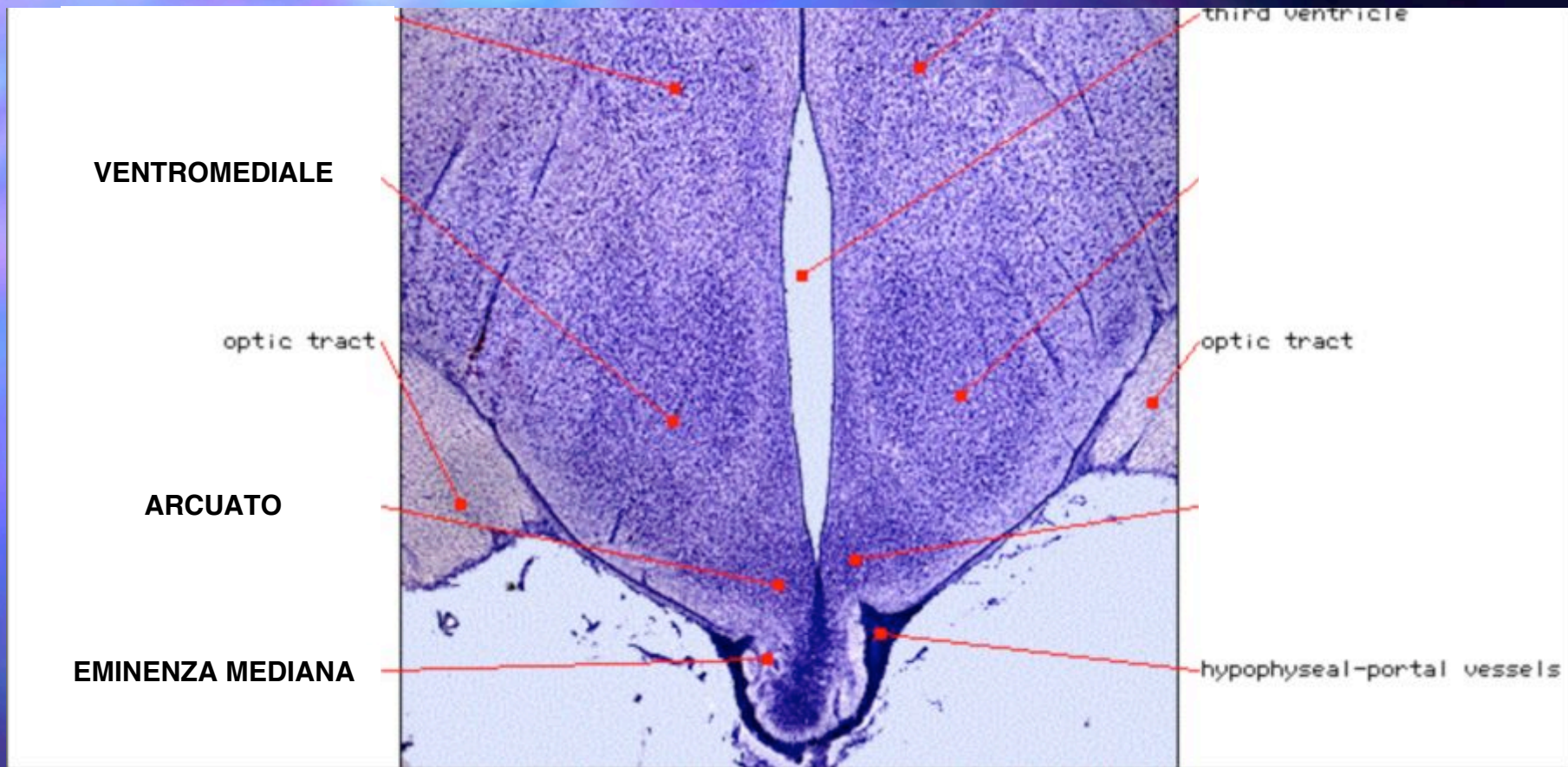
# NEURONI NEUROSECERNENTI IPOTALAMICI

- **MAGNOCELLULARI** - Elementi nervosi i cui neuriti arrivano alla neuroipofisi dove secernono gli ormoni neuroipofisari (vasopressina e ossitocina)
- **PARVOCELLULARI IPOFISIOTROPI** - Elementi nervosi i cui neuriti arrivano all'eminenza mediana ove scaricano RF o IF che regolano l'attività ipofisaria





I neuroni magnocellulari si trovano principalmente nei nuclei paraventricolare e supraottico



I neuroni parvocellulari ipofisiotropi si trovano solo in parte nella regione tuberale (n.ventromediale ed arcuato), ma nella grande maggioranza (TRH, GnRH, SIF) si trovano nel nucleo paraventricolare e nella regione preottica.

I neuroni tuberali (ad esempio dopaminergici) regolano la secrezione dei fattori a livello dell'eminenza mediana.